

Neurology[®]

Table of Contents

Volume 82, Number 5, February 4, 2014
Neurology.org

THE MOST WIDELY READ AND HIGHLY CITED PEER-REVIEWED
NEUROLOGY JOURNAL






IN FOCUS


- 375 Spotlight on the February 4 Issue
389 This Week's *Neurology*[®] Podcast

EDITORIALS

- 376 Treating lacunar strokes occurring on aspirin: Adding clopidogrel is not the simple solution
L. Castilla-Guerra and R.L. Sacco
- 378 Progressive myoclonic epilepsies: It takes a village to make a diagnosis
K. Knupp and E. Wirrell
- 380 Past hormone therapy in older women: Does the brain recover from adverse effects?
K. Kantarci and P.M. Maki

ARTICLES

- 382 ASA failure: Does the combination ASA/clopidogrel confer better long-term vascular protection?
R. Côté, Y. Zhang, R.G. Hart, L.A. McClure, D.C. Anderson, R.L. Talbert, and O.R. Benavente
   **Editorial, p. 376**
- 390 Quantitative sleep stage analyses as a window to neonatal neurologic function
R.A. Shellhaas, J.W. Burns, J.D.E. Barks, and R.D. Chervin
- 396 Electrographic status epilepticus and long-term outcome in critically ill children
K.L. Wagenman, T.P. Blake, S.M. Sanchez, M.T. Schultheis, J. Radcliffe, R.A. Berg, D.J. Dlugos, A.A. Topjian, and N.S. Abend
- 405 Progressive myoclonic epilepsies: Definitive and still undetermined causes
S. Franceschetti, R. Michelucci, L. Canafoglia, P. Striano, A. Gambardella, A. Magaudo, P. Tinuper, A. La Neve, E. Ferlazzo, G. Gobbi, A.T. Giallonardo, G. Capovilla, E. Visani, F. Panzica, G. Avanzini, C.A. Tassinari, A. Bianchi, and F. Zara, on behalf of the Collaborative LICE study group on PMEs
Editorial, p. 378

- 412 Importance of nondopaminergic features in evaluating disease severity of Parkinson disease
J.F. van der Heeden, J. Marinus, P. Martinez-Martin, and J.J. van Hilten
- 417 Comment: Why do nondopaminergic features in Parkinson disease matter?
W. Maetzler
- 419 Aldehyde dehydrogenase variation enhances effect of pesticides associated with Parkinson disease
A.G. Fitzmaurice, S.L. Rhodes, M. Cockburn, B. Ritz, and J.M. Bronstein
- 427 Change in brain and lesion volumes after CEE therapies: The WHIMS-MRI studies
L.H. Coker, M.A. Espeland, P.E. Hogan, S.M. Resnick, R.N. Bryan, J.G. Robinson, J.S. Goveas, C. Davatzikos, L.H. Kuller, J.D. Williamson, C.D. Bushnell, and S.A. Shumaker, for the WHIMS-MRI Study Group
Editorial, p. 380
- 435 Higher RBC EPA + DHA corresponds with larger total brain and hippocampal volumes: WHIMS-MRI Study
J.V. Pottala, K. Yaffe, J.G. Robinson, M.A. Espeland, R. Wallace, and W.S. Harris
- 443 Burden of encephalitis-associated hospitalizations in the United States, 1998–2010
N.M. Vora, R.C. Holman, J.M. Mehal, C.A. Steiner, J. Blanton, and J. Sejvar


HISTORICAL NEUROLOGY

- 452 Tournay's description of anisocoria on lateral gaze: Reaction, myth, or phenomenon?
M.P. Robert and G.T. Plant

CLINICAL/SCIENTIFIC NOTES

- 457 Progressive hemiparesis (Mills syndrome) with aphasia in amyotrophic lateral sclerosis
D. Bäumer, R. Butterworth, R.A.L. Menke, K. Talbot, M. Hofer, and M.R. Turner

OPEN

CONTINUED

Neurology[®]

Table of Contents

continued



NEUROIMAGES

- 459 Wilbrand knee
R.K. Shin, R.A. Qureshi, N.R. Harris, D. Bakar, T.P. Li, M.S. Jafri, and C.-M. Tang

RESIDENT & FELLOW SECTION

- e36 Clinical Reasoning: A 76-year-old man remaining comatose after cardiopulmonary resuscitation
S.C. Li, M.T. de Graaf, and P.J. Cherian
- e41 Pearls & Oysters: Chronic mumps meningoencephalitis with low CSF glucose and acute hydrocephalus in an adult
I. Escalza-Cortina, I. Azkune-Calle, A. Rodriguez-Sainz, M. Gomez-Beldarrain, I. Vicente-Olabarría, and J.C. Garcia-Monco
- e44 Teaching NeuroImages: "Subarachnoid hemorrhage" from decreased contrast elimination after therapeutic hypothermia
W. Mohamed, P. Varade, and G.M. Norris

WRITECLICK: EDITOR'S CHOICE

- 461 Identification of a novel risk variant in the *FUS* gene in essential tremor
G. Kühlenbaeumer; Author Response: E.-K. Tan, Y.-R. Wu
- 461 Propofol-related infusion syndrome heralding a mitochondrial disease: Case report
J. Parness; Author Response: M. Savard, A.F. Turgeon

CORRECTION

- 462 Correction: Copy number variants are frequent in genetic generalized epilepsy with intellectual disability

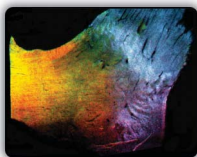DEPARTMENTS

- 463 Book Review
- A21 In the Next Issue of *Neurology*[®]

 Podcast at www.neurology.org  CME  Video  Patient Page  LOE classification  LOE recommendation



tinyurl.com/neurologyfan  twitter.com/GreenJournal



Cover image: Anisotropic scattering imaging of the inferior optic chiasm reveals the arcing path of Wilbrand knee. See page 459.

Look for **Publish Ahead of Print** articles and editorials under the Ahead of Print tab at Neurology.org
